3M/ESPE's RelyX Veneer Luting Cement

Michael A. Miyasaki, DDS

Not only has 3M changed the face of the dental industry by recently merging with ESPE, but now they've introduced a new product- a new veneer luting system with some great properties. Their new product has an original name: "3M/ESPE RelyX Veneer Cement System" (I know, aren't you glad there's another "RelyX" system).

I was intriqued by the cement system because it is a light-cure only luting cement. Since most of the indirect ceramic and resin restorations we place are thin enough or conduct an adequate amount of light to allow us to place them without the use of a dual-cure cement, this shouldn't present a problem with most of its uses. 3M/ESPE has also incorporated a high efficiency photoinitiator into the system which allows the cement to cure more quickly than many of the other cements available.

Why use a light-cured only system?

The benefit of using a light-cured only cement is that it allows us to place multiple units without having to race against the clock and the setting cement when using our Rapid Cementation Technique. The benefit of using a luting cement designed only to be light-cured is that the cement itself does not contain the unreacted amines necessary to react with the peroxides in the catalyst needed as a dual-cure cement. The bottom line is that this makes the cement much more color stable. There's nothing more disheartening than seating a beautiful case and having your patient come back six-months later saying their teeth look darker than before. And this is sometimes a problem with cements that are designed to be both light-cured and dual-cured when used with a catalyst.

Case Study

A 28-year old female patient presented wanting to improve the appearance of her front teeth. She knew she had cavities and did not like the crowded appearance of her teeth. She also wanted a longer, broader and whiter smile. We prepared teeth #4-13 for porcelain restorations. (Figures 1 and 2).

Our clinical examination showed the following:

- Periodontally she was healthy with 2-3 mm pockets and no bleeding on provocation
- Joint and muscle examination showed all within normal limits
- Soft tissue examination was normal
- Deep decay in tooth #6
- Failing restorations on teeth #2, 3, 14 and 31 to be replaced later.

The Seat Appointment

When the patient returned for the seating of the restorations, I elected to anesthetize the patient using the AMSA technique which meant she could feel her upper lip, thereby, allowing us to better determine the patient's aesthetics and comfort as she was leaving for Europe the next day.

The temporary restorations were removed, the preperations were rinsed with hydrogen peroxide, and the restorations were tried in to confirm their fit. The restorations were tried in with the 3M/ESPE Veneer Luting Cement try-in paste. The color match of the try-in pastes with the cured cement is very accurate so I felt confident that what we showed her was the true final shade the teeth were to be. We let the patient see the restorations to confirm she liked. . . no, actually loved, the appearance of her teeth. (Figures 3 and 4).

The try-in paste is water-soluble and was rinsed out thoroughly. The internal surface of the porcelain restorations were reacidified with 35% phosphoric acid, and treated with 3M/ESPE's RelyX Ceramic Primer and dried. They were then coated with 3M/ESPE's Single Bond and covered in a light protected box.

A rubber dam was placed and the teeth were scrubbed with Consepsis, which was then rinsed off. The teeth were sequentially etched to prevent over etching and a rewetting agent, Ultracid, was placed and blotted. Then Single Bond adhesive, which contains ethanol and water, was placed on the teeth, air thinned but not light cured.

All ten veneers were placed on the prepared teeth with the translucent shade of luting cement, the excess was removed, and they were tacked at the gingival margins (Figure 5). The cement has a nice consistency which flows as you seat the restoration and stops flowing once it is seated. This allows you to feel the positive seat, but prevents drift of the restorations once they are placed.

Using the Rapid Cementation Technique meant that excess cement was kept minimal, but this was easily re-

moved with a sharp instrument and very little use of a rotary instrument was needed (Figure 6). The margins were then polished with a composite polishing system.

The patient's occlusion was checked and adjusted, and the porcelain polished.

She sent us a card from Europe thanking us saying she loved her new smile (Figures 7 and 8). Isn't that why we do what we do?

In summary:

The RelyX Veneer Luting Cement has:

1. Accurate color matching of their water soluble try-in pastes and the cured cement
2. Excellent color stability due to its light-cured only chemistry
3. High efficiency light curing
4. Simple shading system of 6 shades
    - Translucent
    - B0.5 / White
    - White Opaque
    - A1 / Light Yellow
    - A3 Opaque / Yellow Opaque
    - A5 / Dark
5. Excellent handling and clean-up
6. Radiopacity

In my opinion 3M/ESPE has a winning product. Their try-in pastes have an excellent color match to the actual cured cement, and the cement's working properties were excellent. Personally, I have used the cement in a number of cases, including full-mouth cases, and have had great results. And comments from other doctors in the LVI clinic using the 3M/ESPE cement on their cases have all been favorable with most saying that the clean-up was very easy when compared to their current system.

Figure 1 - Pre-op full face

Figure 2 - Pre-op smile

Figure 3 - Try-in ten veneers with try-in paste



Figure 4 - Pateint approval

Figure 5 - Ten veneers placed with luting cement

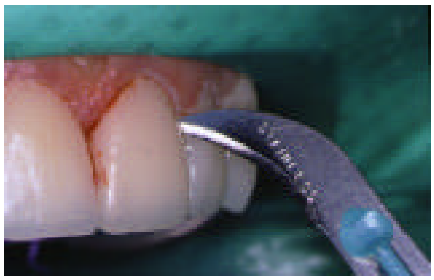

Figure 6 - Easy clean-up

Figure 7 - Retracted immediately after insertion



Figure 8 - Full face immediately after insertion